Immunohistochemical Profile of CD117 and DOG1 in the Diagnosis of Gastrointestinal Stromal Tumors: A Narrative Review

Gita Nawangtantrini[1]
[1]Department of Anatomical Pathology, Faculty of Medicine, Universitas Jenderal Soedirman, Purwokerto, Indonesia
[2]Department of Anatomical Pathology, RSUD Prof. Dr. Margono Soekarjo, Purwokerto, Indonesia
Corresponding email: gita.nawangtantrini@unsoed.ac.id

Abstract

Gastrointestinal stromal tumors (GISTs) are the most common mesenchymal neoplasms of the digestive tract and are driven mainly by activating mutations of KIT or PDGFRA. Because their morphology overlaps with smooth muscle, neural, and other spindle-cell or epithelioid lesions, immunohistochemistry is indispensable for diagnosis, and accurate identification determines eligibility for tyrosine kinase inhibitor therapy. This narrative review aimed to summarize the expression profile, diagnostic performance, and limitations of CD117 and DOG1 in GIST. Original studies, reviews, and guidelines published between 1998 and 2026 were identified through PubMed and Google Scholar and synthesized descriptively. In institutional studies, CD117 positivity ranged from 70% to 100% and DOG1 positivity from 50% to 100%, whereas the largest multisite series reported about 95% for both markers, with DOG1 reaching 94.8% using the K9 clone. DOG1 detected all CD117-negative tumors in three studies and performed better in gastric epithelioid and PDGFRA-mutant GISTs, while CD117 was slightly more sensitive in intestinal tumors. Neither marker was entirely specific. Combined staining identified approximately 97% to 99% of GISTs. A dual CD117 and DOG1 panel is recommended as the first-line approach, with molecular analysis for double-negative or doubtful cases and to guide therapy.

Keywords: CD117; diagnosis; DOG1; gastrointestinal stromal tumor; immunohistochemistry

I. INTRODUCTION

Gastrointestinal stromal tumors (GISTs) are the most frequent mesenchymal neoplasms of the gastrointestinal (GI) tract. They are believed to arise from the interstitial cells of Cajal (ICC), the pacemaker cells that coordinate peristalsis, or from precursor cells capable of differentiating along the ICC lineage (Fatima et al., 2011; Kiśluk et al., 2016). GISTs may develop anywhere from the esophagus to the anus, but the stomach is the predominant site, accounting for approximately 55% of cases, followed by the duodenum and small intestine (30%), the esophagus (5%), the rectum (5%), and the colon (2%) (Fatima et al., 2011). Rarely, they occur in extravisceral sites such as the omentum, mesentery, pelvis, and retroperitoneum (Poveda et al., 2017). Clinically, the presentation is heterogeneous and frequently nonspecific, ranging from incidental small nodules to large masses presenting with gastrointestinal bleeding, abdominal pain, or a palpable lump (Jaypuriya et al., 2022; Tan et al., 2012).

The molecular pathogenesis of GIST was clarified by the discovery that most tumors harbor gain-of-function mutations in the KIT proto-oncogene (Hirota et al., 1998). KIT and the closely related platelet-derived growth factor receptor alpha (PDGFRA) are located on chromosome 4q12 and encode type III receptor tyrosine kinases that, upon ligand binding, dimerize and trigger downstream signaling pathways regulating proliferation, apoptosis, chemotaxis, and adhesion (Rizzo et al., 2016). KIT mutations are found in about 80% of

GISTs, whereas a smaller subset carries PDGFRA mutations in exons 12, 14, or 18 (Fatima et al., 2011). Approximately 95% of GISTs are characterized by mutations in one of these two genes, and the remaining tumors, often termed wild-type GISTs, may be associated with succinate dehydrogenase (SDH) deficiency or other alterations (Kiśluk et al., 2016; Wu et al., 2019).

The recognition of KIT-driven oncogenesis has transformed GIST from a chemoresistant sarcoma into a model of targeted therapy. Tyrosine kinase inhibitors (TKIs) such as imatinib, followed by sunitinib and regorafenib, have markedly improved recurrence-free and overall survival, turning advanced GIST into a chronic disease for many patients (Poveda et al., 2017; Rizzo et al., 2016; Wu et al., 2019). Consequently, the correct pathological diagnosis of GIST is no longer an academic exercise; it determines whether a patient will be offered life-prolonging targeted therapy. Importantly, more than two-thirds of CD117-negative GISTs remain sensitive to imatinib, which means that a missed diagnosis in this subgroup may deprive patients of effective treatment (Şahin et al., 2017).

Histologically, GISTs display spindle-cell, epithelioid, or mixed morphology. This spectrum overlaps substantially with that of leiomyoma, leiomyosarcoma, schwannoma, malignant peripheral nerve sheath tumor, inflammatory myofibroblastic tumor, solitary fibrous tumor, desmoid fibromatosis, and even melanoma or poorly differentiated carcinoma (Fatima et al., 2011; Poveda et al., 2017). Morphology alone is therefore insufficient, and immunohistochemistry (IHC) has become the cornerstone of diagnosis. Before the identification of KIT, CD34 was considered the best available marker, but it is expressed in only 60% to 70% of GISTs, with marked variation by site, and is also positive in fibroblastic, endothelial, and nerve sheath tumors (Fatima et al., 2011; Wu et al., 2019).

CD117, the protein product of KIT, subsequently became the diagnostic hallmark of GIST and is expressed in the majority of tumors with a diffuse cytoplasmic, membranous, or dot-like Golgi pattern (Poveda et al., 2017). However, a clinically relevant proportion of GISTs, reported as approximately 4% to 15%, show weak or absent CD117 immunoreactivity, particularly those with epithelioid morphology or PDGFRA mutations (Fatima et al., 2011; Şahin et al., 2017). This diagnostic gap prompted the search for complementary markers. In 2004, gene expression profiling identified DOG1 (discovered on GIST-1), a calcium-activated chloride channel encoded by ANO1 (also known as TMEM16A) on chromosome 11q13, as a protein highly and selectively expressed in GIST, including KIT-negative cases (Şahin et al., 2017; West et al., 2004). Subsequent studies demonstrated that DOG1 has sensitivity comparable to or exceeding that of CD117 and is particularly useful in unusual subtypes (Liegl et al., 2009; Miettinen et al., 2009).

Current guidelines reflect this evolution. The ESMO–EURACAN–GENTURIS clinical practice guideline (Casali et al., 2022) and the WHO Classification of Digestive System Tumours, 5th edition (WHO Classification of Tumours Editorial Board, 2019), base the diagnosis of GIST on morphology supported by KIT (CD117) and DOG1 immunohistochemistry, and they recommend KIT/PDGFRA mutational analysis and SDHB immunohistochemistry for doubtful, double-negative, and wild-type tumors and to guide treatment.

Despite the wide adoption of both markers, published data on their sensitivity and specificity remain heterogeneous. Reported positivity rates vary according to anatomical site, histological subtype, specimen type, antibody clone, scoring method, and sample size. Some studies have found DOG1 to be clearly superior to CD117, whereas others report the opposite, and several investigations have additionally suggested that DOG1 expression may carry prognostic information (Rizzo et al., 2016; Sözütek et al., 2014; Şahin et al., 2017). For practicing pathologists, particularly in settings where molecular testing is not routinely available, a consolidated understanding of how these two markers perform and complement each other is essential for building efficient and cost-conscious diagnostic algorithms.

From a practical standpoint, the diagnostic challenge is greatest in three situations: small endoscopic or core needle biopsies with limited tumor material, FNA specimens obtained by endoscopic ultrasound, and tumors with unusual morphology or location. In these settings, the pathologist must rely heavily on a small number of well-performing immunohistochemical markers, and the choice of panel directly influences both diagnostic accuracy and laboratory cost (Fatima et al., 2011; Jaypuriya et al., 2022).

Therefore, the objective of this narrative review was to summarize current evidence on the immunohistochemical profile of CD117 and DOG1 in GIST, to compare their diagnostic sensitivity and specificity across anatomical sites, histological subtypes, and specimen types, to identify their individual limitations, and to clarify the rationale for using both markers as a combined first-line diagnostic panel.

II. METHOD

This study was designed as a narrative literature review. Literature searches were conducted in PubMed and Google Scholar using combinations of the following terms: "gastrointestinal stromal tumor", "GIST", "CD117", "c-KIT", "DOG1", "ANO1", "immunohistochemistry", "sensitivity", "specificity", and "diagnosis", linked with the Boolean operators AND and OR. The reference lists of relevant articles were also screened manually to identify additional sources. Publications from 1998, when KIT mutations in GIST were first reported, to 2026 were considered. The search was updated in November 2026 to capture current guidelines (ESMO–EURACAN–GENTURIS, 2022; WHO Classification of Digestive System Tumours, 5th edition, 2019) and recent regional reports from Southeast Asia, including Indonesia.

Articles were included if they (1) were written in English; (2) were original studies evaluating CD117 and/or DOG1 expression by IHC in histologically confirmed GIST, review articles, or clinical practice guidelines addressing the immunohistochemical diagnosis of GIST; and (3) provided extractable data on positivity rates, sensitivity, specificity, or the relationship between marker expression and clinicopathological variables. Case reports, conference abstracts without full text, and studies limited to non-gastrointestinal mesenchymal tumors were excluded.

The methodological quality of each original study was appraised qualitatively, with attention to sample size, presence of a non-GIST control group, specimen type, description of antibody clone and scoring method, and availability of molecular confirmation. These aspects were taken into account when interpreting discrepancies between studies, and studies with small samples or without control groups were interpreted with greater caution. Where a figure was available only in a review article, the original study behind it was identified and cited, and review-derived figures were labeled as secondary-source data.

From each eligible original study, the following information was extracted: first author, year of publication, country, number of GIST cases, specimen type (resection, biopsy, or fine-needle aspiration cell block), CD117 and DOG1 antibody clones, scoring method and positivity cut-off, presence of a non-GIST control group, availability of molecular confirmation, CD117 and DOG1 positivity rates, reported sensitivity and specificity, and major findings regarding anatomical site, histological subtype, antibody clone, and prognosis. Because the included studies differed substantially in design, population, antibody clones, and scoring systems, no quantitative pooling or meta-analysis was performed, and data from the multisite series, which were available to this review only through secondary summaries, were kept separate from those of the institutional studies. Instead, findings were synthesized descriptively and organized thematically into the expression profile of CD117, the expression profile of DOG1, comparative diagnostic performance, determinants of discordance, and

the combined diagnostic approach. Data were summarized in two tables and a comparative figure.

III. RESULTS AND DISCUSSIONS

A. Result

A total of 21 publications were included in this review: nine institutional original studies with extractable CD117 and/or DOG1 data; five landmark primary studies on the discovery and validation of KIT and DOG1 as diagnostic markers (Hirota et al., 1998; Liegl et al., 2009; Lopes et al., 2010; Miettinen et al., 2009; West et al., 2004); one regional molecular study (Ngo et al., 2019) and one Indonesian case report (Putriyuni et al., 2023); two reviews (Tan et al., 2012; Wu et al., 2019); and three guidelines (Poveda et al., 2017; WHO Classification of Tumours Editorial Board, 2019; Casali et al., 2022). The nine institutional studies originated from China, India, Italy, Nigeria, Poland, Turkey, and the United States and collectively evaluated 530 GISTs, with sample sizes ranging from 20 to 111 cases. Eight studies were performed predominantly on surgical resection specimens, while one evaluated fine-needle aspiration (FNA) cell-block material. The multisite series of Miettinen et al. (2009), which examined 1,840 tumors comprising 1,168 GISTs and 672 other tumors and normal tissues, was available to this review only through secondary summaries (Güler et al., 2015; Wu et al., 2019). Wu et al. (2019) report K9-based DOG1 and CD117 results for 1,040 GISTs of gastrointestinal and abdominal origin from that series, whereas Güler et al. (2015) tabulate 1,103 of 1,168 GISTs (94%) as DOG1-positive; the clone comparison of Lopes et al. (2010) involved a different cohort of 668 GISTs. These cohorts are therefore not interchangeable, and they are presented separately from the institutional studies and not pooled with them. The design and methodology of the institutional studies are summarized in Table 1, their positivity rates and principal findings in Table 2, and the comparative positivity rates of CD117 and DOG1 in Figure 1.

CD117 positivity in individual institutional studies ranged from 70% to 100%. In the multisite series of Miettinen et al. (2009), as summarized by Wu et al. (2019), CD117 was expressed in 94.7% of 1,040 GISTs, and early studies with smaller cohorts reported rates of 76% to 100%, giving an overall average of approximately 95%. Similar figures were reported by the Spanish Group for Sarcoma Research (GEIS), which noted CD117 expression in more than 95% of GISTs, with intense staining in about 75% of cases (Poveda et al., 2017). Individual institutional studies reported CD117 positivity of 89% (Şahin et al., 2017), 90.5% (Sun et al., 2012), 92.5% (Jaypuriya et al., 2022), 93.7% (Sözütek et al., 2014), 95.71% (Kiśluk et al., 2016), and 100% (Güler et al., 2015; Rasheed et al., 2023; Rizzo et al., 2016). The lowest sensitivity (70%) was found in FNA cell-block material (Fatima et al., 2011).

DOG1 positivity in institutional studies ranged from 50% to 100%. In the multisite series, DOG1 detected by the monoclonal antibody K9 was positive in 94.8% of 1,040 GISTs (Miettinen et al., 2009, as summarized by Wu et al., 2019). Institutional studies reported DOG1 positivity of 66.1% (39 of 59; Rizzo et al., 2016), 84.1% (Sun et al., 2012), 87.2% (68 of 78 evaluable cases; Sözütek et al., 2014), 88.57% (Kiśluk et al., 2016), 89% (Güler et al., 2015), 90% (Şahin et al., 2017), and 97.5% (Jaypuriya et al., 2022), while a smaller Nigerian series of 20 tumors reported only 50% (Rasheed et al., 2023). In FNA cell blocks, DOG1 achieved 100% sensitivity (Fatima et al., 2011). Sözütek et al. (2014) additionally reported a DOG1 sensitivity of 43% and a specificity of 94%; however, these values were calculated against CD117 status rather than against non-GIST controls, DOG1 could be evaluated in only 78 of 111 tumors because of insufficient tissue, and a polyclonal antibody was used. This value is therefore not comparable with the positivity rates of the other studies and was not included in the range given above.

A consistent finding across studies was the ability of DOG1 to identify CD117-negative GISTs. All CD117-negative tumors were DOG1-positive in the studies by Sun et al. (2012), in which all six CD117-negative cases were DOG1-positive, Fatima et al. (2011), and Şahin et al. (2017). In the study by Jaypuriya et al. (2022), two of three CD117-negative cases were epithelioid tumors, and all epithelioid tumors were DOG1-positive, compared with only 33.33% for CD117. This was not universal: DOG1 was positive in only four of seven CD117-negative tumors in the study of Sözütek et al. (2014), which used a polyclonal antibody, and across published series the proportion of CD117-negative GISTs expressing DOG1 has ranged from 20% to 100% depending on the clone and the series (Güler et al., 2015; Lopes et al., 2010).

Studies that included non-GIST control groups allowed calculation of diagnostic accuracy. In a tissue-based study with 40 GISTs and 28 non-GIST mesenchymal tumors, CD117 showed a sensitivity of 92.50%, specificity of 96.43%, positive predictive value (PPV) of 97.37%, negative predictive value (NPV) of 90.00%, and accuracy of 94.12%, whereas DOG1 showed a sensitivity of 97.50%, specificity of 100%, PPV of 100%, NPV of 96.55%, and accuracy of 98.53% (Jaypuriya et al., 2022). In FNA cell blocks, DOG1 reached 100% sensitivity and specificity, while CD117 showed 70% sensitivity and 76% specificity, increasing to 89% when adenoid cystic carcinomas were excluded, which left spindle-cell neoplasms in the comparison (Fatima et al., 2011). Sun et al. (2012) reported positivity among non-GIST tumors of 11.6% for DOG1 and 16.3% for CD117.

Several studies also evaluated additional markers. CD34 was positive in 62% of GISTs in one cohort (Güler et al., 2015), and in other reports CD34 positivity was 70% to 90%, with actin in 20% to 30%, S-100 in 8% to 10%, and desmin in 2% to 4% of tumors (Poveda et al., 2017). CD34 expression varied by site, being highest in gastric GISTs (85%) and lower in small intestinal GISTs (about 50%) (Fatima et al., 2011). PDGFRA immunostaining was positive in 53.2% of GISTs in one study (Sun et al., 2012) but in 100% in another (Güler et al., 2015). Protein kinase C theta (PKCθ) showed a sensitivity of 40% and specificity of 86% in FNA material (Fatima et al., 2011), and insulin-like growth factor 1 receptor (IGF-1R) was expressed in only 11.43% of GISTs (Kiśluk et al., 2016).

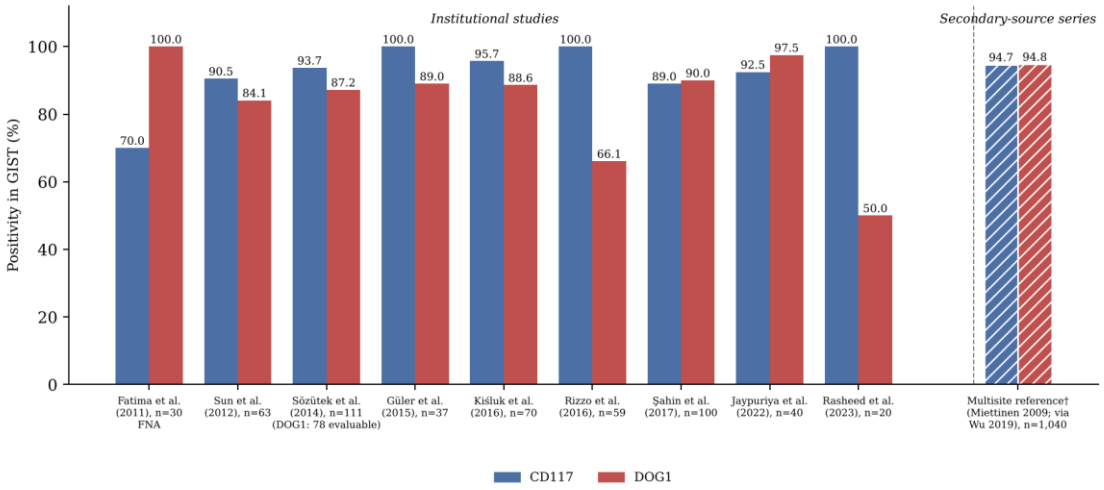

Figure 1. Comparison of CD117 and DOG1 positivity rates in GIST across institutional studies reporting both markers (solid bars) and the multisite reference series obtained through a secondary source (hatched bars).

†Miettinen et al. (2009), n = 1,040 GISTs, as summarized by Wu et al. (2019); shown separately and not pooled with the institutional studies. Sözütek et al.: the DOG1 percentage is based on 78 evaluable cases (68 positive). Rizzo et al.: CD117 was positive in all cases, DOG1 in 39 of 59.

Table 1. Study characteristics and methodology of the institutional studies evaluating CD117 and DOG1 in gastrointestinal stromal tumors

Study	Country	GIST (n)	Specimen	CD117 antibody	DOG1 (+)	Scoring / positivity cut-off	Non-GIST control group	Molecular confirmation
Fatima et al. (2011)	USA	30	FNA cell block	Polyclonal (Dako), 1:200	K9 monoclonal (Leica), RTU	DOG1 Sn/Sp 100%/100%; CD117 Sn/Sp 70%/76% (89% when adenoid cystic carcinomas were excluded); all CD117(–) cases DOG1(+)	Yes (68: 17 leiomyosarcomas, 16 melanomas, 16 schwannomas, 11 adenoid cystic carcinomas, 8 leiomyomas)	No (diagnosis confirmed on biopsy or resection report)
Sun et al. (2012)	China	63	Resection	Monoclonal, clone NR	Monoclonal, clone NR	Positive if ≥5% of cells; + (5–25%), ++ (25–50%), +++ (>50%)	Yes (43 non-GIST mesenchymal tumors)	No
Sözütek et al. (2014)	Turkey	111	Resection	93.7%	87.2%‡	DOG1 assessable in 78 of 111 cases; reported Sn/Sp of 43%/94% were calculated against CD117, not against non-GIST controls; DOG1(+) in 4 of 7 CD117(–) cases	No	No
Güler et al. (2015)	Turkey	37	Resection	Polyclonal C-19 (Santa Cruz), 1:200	SP31 monoclonal (Thermo), 1:50	Positive if >10% of cells; 10–50% focal, >50% diffuse	No	No
Kiśluk et al. (2016)	Poland	70	Resection	Polyclonal (Abcam), 1:100	K9 monoclonal (Thermo Scientific), RTU	Positive if >20% of cells	No	No
Rizzo et al. (2016)	Italy	59	Resection	100%	66.1%	All cases CD117(+); strong DOG1 associated with size, wild-type status, and worse 2-year RFS	No	Yes (KIT exons 9, 11, 13, 17 and PDGFRA exons 12, 18 sequenced in 53 cases)
Şahin et al. (2017)	Turkey	100	Resection	NR	K9 monoclonal (Leica), RTU	Extent × intensity (index 0–9); positive if ≥10% of cells	No	No
Jaypuriya et al. (2022)	India	40	Resection	NR†	DOG1.1 monoclonal	Staining ratio score (low 0–2, high 3–4) and intensity; cut-off NR	Yes (28 non-GIST tumors)	No
Rasheed et al. (2023)	Nigeria	20	Resection/biopsy	Monoclonal, clone NR, 1:20	Monoclonal, clone NR, 1:20	Stomach 70%; spindle type 80%; clone and cut-off not reported	No (manufacturer controls only)	No (not available)
Miettinen et al. (2009)§	Multisite	1,040	Resection	94.7%	94.8%	K9; summarized by Wu et al. (2019); CD117/DOG1 concordance 92.3%; DOG1 better in gastric epithelioid and PDGFRA-mutant tumors, less sensitive in intestinal tumors; 27 GISTs (2.6%) negative for both	No (manufacturer controls only)	No (not available)
Lopes et al. (2010)§	NR	668	Resection	96%	K9 96.1%; DOG1.1 80.5%	Clone comparison; among 25 KIT-negative GISTs, K9 detected 76% and DOG1.1 20% (as tabulated by Güler et al., 2015; Wu et al., 2019)	No (manufacturer controls only)	No (not available)

Notes: FNA = fine-needle aspiration; NR = not reported; RTU = ready to use. Molecular confirmation refers to KIT/PDGFRA mutational analysis. †The antibody table was not legible in the version of the article available to this review. Clones are given as reported by the authors.

Table 2. Positivity rates and principal findings of the institutional studies evaluating CD117 and DOG1 in gastrointestinal stromal tumors, with multisite reference series shown separately

Study	Country	GIST (n)	Specimen	CD117 (+)	DOG1 (+)	Main findings
Fatima et al. (2011)	USA	30	FNA cell block	70%	100%	DOG1 Sn/Sp 100%/100%; CD117 Sn/Sp 70%/76%; all CD117(–) cases DOG1(+)
Sun et al. (2012)	China	63	Resection	90.5%	84.1%	All 6 CD117(–) cases DOG1(+); non-GIST positivity 16.3% (CD117) vs 11.6% (DOG1)
Sözütek et al. (2014)	Turkey	111	Resection	NR	43%	DOG1 Sp 94%; useful in c-kit(–) cases
Güler et al. (2015)	Turkey	37	Resection	100%	89%	CD117 remains key; DOG1 useful as adjunct; CD34 62%
Kiśluk et al. (2016)	Poland	70	Resection	95.71%	88.57%	DOG1 correlated with histological type; no survival association
Rizzo et al. (2016)	Italy	59	Resection	NR	66%*	Strong DOG1 associated with size, wild-type status, worse 2-year RFS
Şahin et al. (2017)	Turkey	100	Resection	89%	90%	All CD117(–) cases DOG1(+); high DOG1 index linked to poorer OS
Jaypuriya et al. (2022)	India	40	Resection	92.5%	97.5%	DOG1 Sn/Sp 97.5%/100% vs CD117 92.5%/96.43%; epithelioid: CD117 33.3% vs DOG1 100%
Rasheed et al. (2023)	Nigeria	20	Resection	100%	50%	Stomach 70%; spindle type 80%

Notes: FNA = fine-needle aspiration; NR = not reported; OS = overall survival; RFS = recurrence-free survival; Sn = sensitivity; Sp = specificity. ‡Percentage based on the 78 evaluable cases (68 positive); the reported 43% sensitivity is not a positivity rate (see text). §Secondary-source data, not pooled with the institutional studies; Lopes et al. (2010) is shown for the clone comparison only (DOG1 K9 / DOG1.1).

With respect to staining quality, DOG1 generally produced stronger and more uniform staining. Strong DOG1 immunoreactivity was observed in 75% of cases compared with 32.5% for CD117, and a high staining ratio score was observed in 95% versus 87.5% of cases, respectively (Jaypuriya et al., 2022). CD117 staining ratio varied significantly by histological type and risk group, whereas DOG1 expression remained relatively constant. Agreement between the two markers in that study was moderate (kappa = 0.481). In the multisite series of Miettinen et al. (2009), CD117 and DOG1 results were concordant in 92.3% of GISTs (as summarized by Wu et al., 2019).

Regarding prognosis, findings were inconsistent. Strong DOG1 expression was associated with tumor size, wild-type status, and worse two-year recurrence-free survival (Rizzo et al., 2016), and a high DOG1 immunostaining index was independently associated with poorer overall survival (Şahin et al., 2017). In contrast, other studies found no association between CD117 or DOG1 expression and risk category or survival (Kiśluk et al., 2016; Sun et al., 2012), and Sözütek et al. (2014) observed only a non-significant trend toward shorter survival in DOG1-negative advanced-stage disease ($p = 0.061$), which is the opposite direction.

B. Discussion

This review confirms that CD117 and DOG1 are both highly sensitive markers for GIST, but that each has distinct strengths and blind spots. The overall picture is one of complementarity rather than competition: DOG1 tends to recover the tumors that CD117 misses, CD117 occasionally identifies tumors with weak DOG1 staining, and the combination of the two covers approximately 97% to 99% of GISTs (Kiśluk et al., 2016; Wu et al., 2019).

The evolution of GIST immunodiagnosis illustrates how molecular discoveries translate into routine pathology. The identification of KIT gain-of-function mutations established CD117 as the first specific marker (Hirota et al., 1998), and the discovery of DOG1 through gene expression profiling showed that a marker could be expressed irrespective of KIT or PDGFRA mutation status (West et al., 2004). Later validation in large series, including the study of Miettinen et al. (2009) of 1,840 tumors comprising 1,168 GISTs and 672 other tumors and normal tissues, confirmed that DOG1 is almost as sensitive as KIT and is valuable in KIT-negative and unusual subtypes (Liegl et al., 2009; Miettinen et al., 2009; Wu

et al., 2019). The institutional studies summarized in this review, conducted across different continents and laboratory settings, largely reproduce these findings, although DOG1 positivity varied considerably, which supports the combined approach rather than reliance on either marker alone.

CD117 remains a robust and widely validated marker. Its average positivity of approximately 95% and its near-universal absence in principal mimics such as leiomyoma, leiomyosarcoma, and schwannoma make it both sensitive and specific in most diagnostic contexts (Wu et al., 2019). Its diagnostic value is enhanced by the fact that immunohistochemical positivity is largely independent of the specific KIT or PDGFRA mutation present (Poveda et al., 2017). However, the variability of CD117 positivity among studies has been attributed to differences in primary tumor location, antibody selection, and limited case numbers (Wu et al., 2019). The most important biological limitation is reduced expression in epithelioid GISTs and in tumors driven by PDGFRA mutations, which are concentrated in the stomach. This pattern was illustrated in the study by Jaypuriya et al. (2022), where only one of three epithelioid GISTs expressed CD117, and CD117 staining ratio was significantly lower in epithelioid tumors ($p = 0.011$). Furthermore, CD117 staining intensity was variable, with strong staining in only one-third of cases, which may lead to equivocal interpretation in small biopsies or poorly fixed tissue.

A second limitation of CD117 relates to specificity outside the narrow differential diagnosis of spindle-cell GI tumors. CD117 can be expressed by mast cells, melanoma, seminoma, adenoid cystic carcinoma, and some other neoplasms. In the FNA study by Fatima et al. (2011), CD117 specificity rose from 76% to 89% when adenoid cystic carcinomas were excluded, indicating that a substantial fraction of false-positive results came from non-mesenchymal tumors. This observation emphasizes that CD117 must always be interpreted in the context of morphology and the clinical setting.

Correct interpretation also depends on familiarity with the staining patterns of each marker. CD117 in GIST typically shows diffuse cytoplasmic staining, often accompanied by membranous accentuation, and a perinuclear dot-like Golgi pattern may be seen, particularly in epithelioid tumors (Poveda et al., 2017). DOG1, as a transmembrane chloride channel, usually produces membranous and cytoplasmic staining that is strong and diffuse in most tumors (Jaypuriya et al., 2022; West et al., 2004). Pathologists should be aware that mast cells provide a convenient internal positive control for CD117, whereas DOG1 may stain normal ICC within the muscularis propria, which can serve as an internal control but should not be mistaken for tumor infiltration. Focal or weak staining in only a minority of tumor cells should be interpreted cautiously, especially when morphology is atypical, and in such cases the second marker is particularly valuable.

DOG1 addresses several of these limitations. Its expression appears to be largely independent of KIT and PDGFRA mutation status, which explains why it is retained in CD117-negative and PDGFRA-mutant tumors (Şahin et al., 2017; Wu et al., 2019). The finding that all CD117-negative GISTs were DOG1-positive in three independent cohorts (Fatima et al., 2011; Sun et al., 2012; Şahin et al., 2017) is clinically highly relevant, as many of these patients may still benefit from TKI therapy. The GEIS guideline accordingly describes DOG1 as an almost pathognomonic marker that can be included in the initial panel and is highly recommended when CD117 is negative (Poveda et al., 2017). In addition, DOG1 staining is generally stronger and less variable across histological subtypes and risk categories, which facilitates interpretation, particularly in limited material such as endoscopic biopsies and FNA cell blocks (Fatima et al., 2011; Jaypuriya et al., 2022).

The value of DOG1 is particularly striking in cytological material. Endoscopic ultrasound-guided FNA allows preoperative diagnosis and may enable neoadjuvant TKI therapy for large or unfavorably located tumors. In FNA cell blocks, DOG1 maintained 100% sensitivity and specificity, whereas CD117 sensitivity dropped to 70%, and IHC results

on cell blocks were fully concordant with those of subsequent resection specimens (Fatima et al., 2011). These data suggest that DOG1 should be routinely included whenever GIST is suspected in limited preoperative samples, where the consequences of a false-negative result are greatest.

Nevertheless, DOG1 is not perfect. In the multisite series of Miettinen et al. (2009), as summarized by Wu et al. (2019), DOG1 was slightly less sensitive than CD117 in intestinal GISTs, while it performed better in gastric epithelioid and PDGFRA-mutant tumors. This site-related difference likely reflects the distribution of molecular and histological subtypes along the GI tract: intestinal GISTs are predominantly spindle-cell tumors with KIT mutations that express CD117 strongly, so the relative advantage of DOG1 is less evident, whereas the epithelioid and PDGFRA-mutant tumors in which DOG1 excels are concentrated in the stomach. The precise molecular mechanism for site-dependent differences in ANO1 expression remains incompletely understood and represents a gap in current knowledge. DOG1 also lacks absolute specificity. Expression has been documented in uterine-type retroperitoneal leiomyomas (5 of 42), peritoneal leiomyomatosis (4 of 17), synovial sarcomas (6 of 37), and some esophageal squamous cell and gastric carcinomas, although the latter are usually easily distinguishable by morphology (Wu et al., 2019).

Technical factors substantially influence DOG1 performance. In the comparison of two monoclonal antibodies in 668 GISTs by Lopes et al. (2010), the K9 clone was positive in 96.1% of tumors compared with 80.5% for DOG1.1, and in 25 KIT-negative GISTs, K9 detected 76% versus only 20% for DOG1.1 (as summarized by Wu et al., 2019). As shown in Table 1, the institutional studies used different DOG1 reagents, including K9 (Fatima et al., 2011; Kiśluk et al., 2016; Rizzo et al., 2016; Şahin et al., 2017), SP31 (Güler et al., 2015), DOG1.1 (Jaypuriya et al., 2022), and a polyclonal antibody (Sözütek et al., 2014), whereas the clone was not reported by Sun et al. (2012) or Rasheed et al. (2023). Positivity thresholds also ranged from any convincing staining to more than 20% of tumor cells, and scoring systems differed. These differences may partly explain the wide range of DOG1 positivity. The lowest value, 50%, was reported by Rasheed et al. (2023), in which neither the clone nor a cut-off was stated, so the contribution of the antibody cannot be verified. The 43% sensitivity reported by Sözütek et al. (2014) reflects a polyclonal antibody and a calculation against CD117 status rather than a true positivity rate, as discussed above. Additional contributors include small sample size, preanalytical variables such as fixation time and tissue processing, and the age of archival blocks. These observations underline that laboratories adopting DOG1 should select a well-validated clone, use appropriate external quality control, and include a known positive control in every run.

The two markers show high but imperfect concordance, ranging from moderate agreement (kappa = 0.481) in a single-center study to 92.3% concordance in the multisite series of Miettinen et al. (2009) (Jaypuriya et al., 2022; Wu et al., 2019). Discordant cases are diagnostically the most important because they represent the tumors that would be missed by a single-marker strategy. When both markers are applied together, only approximately 1% to 2.6% of GISTs remain negative for both (Kiśluk et al., 2016; Wu et al., 2019), corresponding to roughly 97% to 99% coverage. This substantial reduction in false-negative results is the main rationale for recommending combined staining as the first-line approach. Moreover, the cost of adding a second marker is modest compared with the consequences of a missed diagnosis, which may include denial of adjuvant TKI therapy or unnecessary additional workup.

Ancillary markers retain a supportive role but cannot replace CD117 and DOG1. CD34 is neither sufficiently sensitive nor specific, being expressed in only about two-thirds of GISTs and also in fibroblastic, endothelial, and nerve sheath tumors (Fatima et al., 2011; Wu et al., 2019). PDGFRA immunostaining yielded inconsistent results across studies (Güler et al., 2015; Sun et al., 2012), and PKCθ and IGF-1R showed low sensitivity (Fatima et al., 2011;

Kiśluk et al., 2016). Their main contribution is in the differential diagnosis of double-negative tumors, where desmin and smooth muscle actin favor smooth muscle neoplasms and S-100 favors schwannoma or melanoma. SDHB loss, in contrast, is a useful marker for identifying SDH-deficient GISTs, which are typically gastric, often occur in young patients, and usually lack KIT and PDGFRA mutations (Poveda et al., 2017; Wu et al., 2019).

Based on the reviewed evidence, a practical stepwise diagnostic algorithm can be proposed. In tumors with morphology suggestive of GIST, the first panel should consist of CD117 and DOG1. Positivity for either marker in an appropriate morphological and clinical context supports the diagnosis of GIST. If both are negative, a second panel including CD34, smooth muscle actin, desmin, and S-100 helps exclude smooth muscle and neural tumors, and SDHB immunostaining may identify SDH-deficient GISTs (Jaypuriya et al., 2022; Poveda et al., 2017). Cases that remain unresolved should be referred for molecular analysis of KIT and PDGFRA, because these results not only confirm the diagnosis but also guide the choice and dosing of TKI therapy (Poveda et al., 2017; Wu et al., 2019). Notably, among GISTs negative for both CD117 and DOG1, a substantial proportion are KIT/PDGFRA wild-type, and these cases should be discussed in a multidisciplinary team (Wu et al., 2019). This approach is consistent with current guidelines, which define the diagnosis of GIST by morphology supported by KIT (CD117) and DOG1 expression and recommend KIT/PDGFRA mutational analysis and SDHB immunohistochemistry for doubtful or double-negative tumors (Casali et al., 2022; WHO Classification of Tumours Editorial Board, 2019).

The reported prognostic role of DOG1 deserves comment. Two studies suggested that strong DOG1 expression is associated with worse recurrence-free or overall survival (Rizzo et al., 2016; Şahin et al., 2017), and DOG1 has been linked biologically to downstream RAS/RAF/MEK/ERK and insulin-like growth factor signaling (Şahin et al., 2017). However, other studies did not find an association with risk category or survival (Kiśluk et al., 2016; Sun et al., 2012), and Sözütek et al. (2014) found only a non-significant trend in the opposite direction. At present, established risk stratification remains based on tumor size, mitotic count, site, and rupture, and DOG1 should be regarded primarily as a diagnostic rather than a prognostic marker until validated in larger prospective cohorts.

These findings have particular relevance for resource-limited settings, including many hospitals in Indonesia. Current guidelines recommend KIT/PDGFRA mutational analysis to guide treatment (Casali et al., 2022), but molecular testing is not routinely available or affordable in many centers. In such contexts, a well-performed dual CD117 and DOG1 panel can establish the diagnosis in the great majority of cases, so that limited genetic testing can be prioritized for double-negative or atypical cases and for patients who are candidates for targeted therapy. Regional data underline this need: KIT mutations were found in 68 of 100 Vietnamese GISTs, mostly in exon 11 (Ngo et al., 2019), and a Thai series of 76 GISTs reported CD117 and DOG1 positivity of 98.7% and 100% (Jumniensuk & Charoenpitakchai, 2018, as cited in Jaypuriya et al., 2022). Published Indonesian data on CD117 and DOG1 are scarce; the only report identified in this review was a case of GIST of the prostate diagnosed on transurethral resection, in which CD117, CD34, and DOG1 were all positive (Putriyuni et al., 2023). Standardization of antibody clones, staining protocols, and scoring criteria across laboratories would further improve reproducibility.

This review has several limitations. As a narrative review, it did not follow a formal systematic search protocol, and selection bias cannot be excluded, and although the search was extended to 2026, it was not exhaustive. The included studies were heterogeneous in sample size, specimen type, antibody clones, cut-off values, and reference standards, which precluded meta-analysis. Several studies had small sample sizes or lacked non-GIST control groups, limiting the precision of sensitivity and specificity estimates. Molecular confirmation was not available in all cohorts. Future systematic reviews and multicenter studies using

standardized clones and molecular reference standards are needed, particularly in Southeast Asian populations, for which published data remain scarce. In addition, key multisite figures were available only through secondary summaries rather than the original publications, antibody clones, cut-offs, and molecular data were not reported uniformly across studies (Table 1), and primary data from Southeast Asia, particularly Indonesia, were scarce.

IV. CONCLUSION

CD117 and DOG1 are both highly sensitive immunohistochemical markers for GIST, with average positivity of about 95% in the largest multisite series, but each has specific limitations: CD117 is less reliable in epithelioid and PDGFRA-mutant gastric tumors, whereas DOG1 is slightly less sensitive in intestinal tumors, depends strongly on antibody clone, and may be expressed in a few non-GIST neoplasms. Because DOG1 detects most CD117-negative tumors and the combination of both markers identifies approximately 97% to 99% of GISTs, a dual CD117 and DOG1 panel interpreted together with morphology should be adopted as the first-line diagnostic approach, with additional markers and KIT/PDGFRA molecular analysis for double-negative or diagnostically uncertain cases and to guide targeted therapy.

ACKNOWLEDGEMENT

The author thanks colleagues at the Department of Anatomical Pathology, Faculty of Medicine, Universitas Jenderal Soedirman, and RSUD Prof. Dr. Margono Soekarjo, Purwokerto, for their support in the preparation of this manuscript.

REFERENCES

Casali, P. G., Blay, J. Y., Abecassis, N., et al. (2022). Gastrointestinal stromal tumours: ESMO–EURACAN–GENTURIS clinical practice guideline for diagnosis, treatment and follow-up. *Annals of Oncology*, *33*(1), 20–33. https://doi.org/10.1016/j.annonc.2021.09.005

Fatima, N., Cohen, C., & Siddiqui, M. T. (2011). DOG1 utility in diagnosing gastrointestinal stromal tumors on fine-needle aspiration. *Cancer Cytopathology*, *119*(3), 202–208. https://doi.org/10.1002/cncy.20149

Güler, B., Özyılmaz, F., Tokuç, B., Can, N., & Taştekin, E. (2015). Histopathological features of gastrointestinal stromal tumors and the contribution of DOG1 expression to the diagnosis. *Balkan Medical Journal*, *32*(4), 388–396. https://doi.org/10.5152/balkanmedj.2015.15912

Hirota, S., Isozaki, K., Moriyama, Y., Hashimoto, K., Nishida, T., Ishiguro, S., Kawano, K., Hanada, M., Kurata, A., Takeda, M., Muhammad Tunio, G., Matsuzawa, Y., Kanakura, Y., Shinomura, Y., & Kitamura, Y. (1998). Gain-of-function mutations of c-kit in human gastrointestinal stromal tumors. *Science*, *279*(5350), 577–580. https://doi.org/10.1126/science.279.5350.577

Jaypuriya, A., Gupta, G. N., Faujdar, M., & Gupta, S. (2022). Study from tertiary care centre elucidating the role of CD 117 & DOG 1 antibodies in diagnosis of gastrointestinal stromal tumors. *International Journal of Research and Review*, *9*(8), 678–689. https://doi.org/10.52403/ijrr.20220856

Kiśluk, J., Zińczuk, J., Kemona, A., Guzińska-Ustymowicz, K., Żurawska, J., & Kędra, B. (2016). Expression of CD117, DOG-1, and IGF-1R in gastrointestinal stromal tumours

– An analysis of 70 cases from 2004 to 2010. *Gastroenterology Review*, *11*(2), 115–122. https://doi.org/10.5114/pg.2015.52587

Liegl, B., Hornick, J. L., Corless, C. L., & Fletcher, C. D. M. (2009). Monoclonal antibody DOG1.1 shows higher sensitivity than KIT in the diagnosis of gastrointestinal stromal tumors, including unusual subtypes. *The American Journal of Surgical Pathology*, *33*(3), 437–446. https://doi.org/10.1097/PAS.0b013e318186b158

Lopes, L. F., West, R. B., Bacchi, L. M., van de Rijn, M., & Bacchi, C. E. (2010). DOG1 for the diagnosis of gastrointestinal stromal tumor (GIST): Comparison between 2 different antibodies. *Applied Immunohistochemistry & Molecular Morphology*, *18*(4), 333–337.

Miettinen, M., Wang, Z.-F., & Lasota, J. (2009). DOG1 antibody in the differential diagnosis of gastrointestinal stromal tumors: A study of 1840 cases. *The American Journal of Surgical Pathology*, *33*(9), 1401–1408. https://doi.org/10.1097/PAS.0b013e3181a90e1a

Ngo, Q. D., Pham, Q. T., Phan, D. A. T., Hoang, A. V., Hua, T. N. H., & Nguyen, S. T. (2019). Molecular and clinicopathological features of gastrointestinal stromal tumors in Vietnamese patients. *Journal of Pathology and Translational Medicine*, *53*(6), 361–368. https://doi.org/10.4132/jptm.2019.08.27

Poveda, A., García del Muro, X., López-Guerrero, J. A., Cubedo, R., Martínez, V., Romero, I., Serrano, C., Valverde, C., & Martín-Broto, J. (2017). GEIS guidelines for gastrointestinal sarcomas (GIST). *Cancer Treatment Reviews*, *55*, 107–119. https://doi.org/10.1016/j.ctrv.2016.11.011

Putriyuni, A., Zulfiqar, Y., Saberko, S., & Indrati, L. (2023). Diagnostic challenges of gastrointestinal stromal tumour during transurethral resection of the prostate: A case report. *JKKI: Jurnal Kedokteran dan Kesehatan Indonesia*. https://doaj.org/article/70f3d6eb39294f33b1a00c06f200a6b9

Rasheed, M. W., Abiodun, A. E., Eziagu, U. B., Idowu, N. A., Kabiru, A., Adegboye, T. A., et al. (2023). Clinicopathological and immunohistochemical characterization of gastrointestinal stromal tumour at four tertiary health centers in Nigeria using CD117, DOG1, and human epidermal growth factor receptor-2 biomarkers. *Annals of African Medicine*, *22*(4), 501–507. https://doi.org/10.4103/aam.aam_180_22

Rizzo, F. M., Palmirotta, R., Marzullo, A., Resta, N., Cives, M., Tucci, M., & Silvestris, F. (2016). Parallelism of DOG1 expression with recurrence risk in gastrointestinal stromal tumors bearing KIT or PDGFRA mutations. *BMC Cancer*, *16*, 87. https://doi.org/10.1186/s12885-016-2111-x

Şahin, S., Ekinci, Ö., Seçkin, S., & Dursun, A. (2017). The diagnostic and prognostic utility of DOG1 expression on gastrointestinal stromal tumors. *Turkish Journal of Pathology*, *33*(1), 1–8. https://doi.org/10.5146/tjpath.2016.01376

Sözütek, D., Yanık, S., Akkoca, A. N., Sözütek, A., Özdemir, Z. T., Avşar, Ç. U., Günaldı, M., Şahin, B., & Doron, F. (2014). Diagnostic and prognostic roles of DOG1 and Ki-67 in GIST patients with localized or advanced/metastatic disease. International Journal of Clinical and Experimental Medicine, 7(7), 1914–1922. https://pmc.ncbi.nlm.nih.gov/articles/PMC4132165/

Sun, X.-W., Feng, Z.-J., Huang, P., Hao, W., & Sui, X.-L. (2012). Expression of DOG1, CD117 and PDGFRA in gastrointestinal stromal tumors and correlations with

clinicopathology. *Asian Pacific Journal of Cancer Prevention*, *13*(4), 1389–1393. https://doi.org/10.7314/APJCP.2012.13.4.1389

Tan, C. B., Zhi, W., Shahzad, G., & Mustacchia, P. (2012). Gastrointestinal stromal tumors: A review of case reports, diagnosis, treatment, and future directions. *ISRN Gastroenterology*, *2012*, 595968. https://doi.org/10.5402/2012/595968

West, R. B., Corless, C. L., Chen, X., Rubin, B. P., Subramanian, S., Montgomery, K., Zhu, S., Ball, C. A., Nielsen, T. O., Patel, R., Goldblum, J. R., Brown, P. O., Heinrich, M. C., & van de Rijn, M. (2004). The novel marker, DOG1, is expressed ubiquitously in gastrointestinal stromal tumors irrespective of KIT or PDGFRA mutation status. *The American Journal of Pathology*, *165*(1), 107–113. https://doi.org/10.1016/S0002-9440(10)63279-8

WHO Classification of Tumours Editorial Board. (2019). *Digestive system tumours* (5th ed.). International Agency for Research on Cancer.

Wu, C.-E., Tzen, C.-Y., Wang, S.-Y., & Yeh, C.-N. (2019). Clinical diagnosis of gastrointestinal stromal tumor (GIST): From the molecular genetic point of view. *Cancers*, *11*(5), 679. https://doi.org/10.3390/cancers11050679